CASE REPORT

Hepatic focal nodular hyperplasia: when a benign lesion becomes "malignant". Report of a case

Papanikolaou V[1], Vrochides D[1], Margari P[2], Giakoustidis D[1], Antoniadis N[1], Tsinoglou K[3], Akriviadis E[2], Takoudas D[1]

[1] Organ Transplant Unit, Aristotle University, Thessaloniki, Greece
[2] Department of Internal Medicine, Aristotle University, Thessaloniki, Greece
[3] Department of Radiology, Aristotle University, Thessaloniki, Greece

Abstract
In a 34 year-old woman complaining of right upper quadrant pain and having mildly elevated total bilirubin, the imaging investigation revealed a liver lesion with characteristics of focal nodular hyperplasia, measuring 3.8 cm, at the confluence of the hepatic veins. The mass was obstructing the left and middle hepatic veins and nearly obstructing the right hepatic vein. Dilation of the splenic vein with development of retropancreatic varices, splenomegaly and free abdominal fluid were also present. The patient underwent an uncomplicated left hemihepatectomy. Patient's postoperative total bilirubin was normalized. Tomographic imaging three months after the liver resection revealed resolution of all the Budd-Chiari radiographic signs. This is a report of a case where a hepatic focal nodular hyperplasia, despite its benign nature, required extensive and urgent surgical intervention due to its location and potential dangers secondary to the development of portal hypertension. Hippokratia 2009; 13 (2): 114-115

Keywords: focal nodular hyperplasia, Budd-Chiari, liver resection, portal hypertension

Corresponding author: Margari P, Hippokratio Hospital, 49, Konstantinoupoleos Str, 54642, Thessaloniki, Greece, Tel/Fax: +30 2310 +855566, e-mail: vaspap@med.auth.gr

In March 2008, a 34 year-old woman presented to her primary care physician complaining of mild right upper quadrant pain that started two months ago. She was consuming alcohol only socially and she had never smoked. She gave birth to three healthy children. She had never received any contraceptives. Her family history was essentially free. Her physical exam was unremarkable. Past medical and surgical history was noncontributory except the fact that she had another episode with similar symptoms three years ago that resolved spontaneously one month later. At that time, she had undergone an extensive work-up (including CT imaging, esophagogastroscopy and colonoscopy) that was negative. This time however, work-up was more revealing. Total bilirubin was elevated to 1.8 mg/dl. The rest of blood chemistry, including hepatitis panel and tumor markers (α-Fp, CA19-9, CEA, CA125) was within normal limits. An abdominal ultrasound revealed a liver lesion at the confluence of the hepatic veins (segments IVa and I), measuring 3.8 cm. This lesion was further characterized by triple phase contrast, multi-detector (64) CT and by T1/T2 weighted MRI. The mass was obstructing the left and middle hepatic veins and nearly obstructing the right hepatic vein (Figure 1). The lesion had the typical appearance of focal nodular hyperplasia (FNH). In addition, the CT revealed signs of portal hypertension including dilation of the splenic vein with development of retropancreatic varices, splenomegaly and free abdominal fluid (Figure 2). The spleen size was calculated by CT volumetrics to be 327 cm^3. Given the fact that hepatic veins were found to be dilated too, the working diagnosis was finalized as follows: a small FNH lesion, located at the confluence of the hepatic veins, obstructs the hepatic outflow, leading to Budd-Chiari Syndrome (BCS).

The decision was made to proceed with surgical resection of the lesion. The patient underwent an uncomplicated left hemihepatectomy (segments I, II, III and IV). The left and middle hepatic veins were included into the specimen. Patient's total bilirubin on the 10th post-

Figure 1: Triple phase contrast CT (spiral) revealed that the left and middle hepatic veins (white arrows) were obstructed by the tumor, where as the right hepatic vein (black arrow) was nearly obstructed.

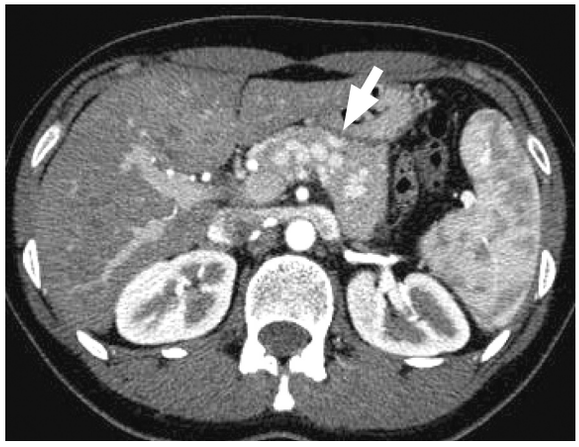

Figure 2: The portal phase of the spiral CT revealed an extensive network of retropancreatic varices (white arrow) together with a dilated portalvein.

operative day was 0.7 mg/dl. A CT scan performed the same day revealed complete decompression of the right hepatic vein and the retrohepatic inferior vena cava. The

Figure 3: Three months after hepatectomy, the portal phase of the spiral CT revealed complete collapse of the retropancreatic varices.

outpatient follow-up was unremarkable. She maintained a normal total bilirubin value. A CT scan on the 90th postoperative day showed a splenic vein with normal size, collapse of the retropancreatic varices and absence of intraperitoneal free fluid (Figure 3). She remained well on her last visit to the Outpatient Clinic in July 2008.

Despite some rare reports of either spontaneous rupture[1] or radiographic misdiagnosis[2] of an FNH, the benign nature of this lesion is well established and the current recommendations favor its observation and not its surgical resection[3]. In addition, BCS is associated with the presence of regenerative nodules that are FNH-like in almost half of the cases. These lesions are developed as a consequence of the BCS, after the development of compensatory arterial hyperemia[4]. In contrast, in our patient, a single FNH was the cause and not the consequence of BCS. Due to its location and the forthcoming complications related with the evolution of BCS, this otherwise benign lesion needed to be treated as a "malignant" one, i.e. with surgical resection. The success of the chosen treatment is reflected not only in qualitative parameters (splenic vein normalization, collapse of the retropancreatic varices, absence of intraperitoneal free fluid) but in quantitive parameters too, i.e. the total bilirubin value. As a final comment, when the patient had the same symptoms three years ago, she had undergone a plain abdominal CT that was normal. This time, she underwent a triple phase contrast CT that revealed the lesion (enhances strongly at the arterial phase). It is tempting to assume that, if she had undergone either a sonogram or a triple phase contrast CT three years ago, the lesion (smaller of course) would have been disclosed earlier. We constantly need to keep in mind that whenever we investigate symptoms that might come from the liver, the imaging modalities of choice are the sonogram and the triple phase contrast CT (spiral) and not the plain single phase contrast abdominal CT scan.

References

1. Reddy KR, Kligerman S, Levi J, et al. Benign and solid tumors of the liver: relationship to sex, age, size of tumors and outcome. Am Surg 2001; 67: 173- 178
2. Yamamoto M, Ariizumi S, Yoshitoshi K, Saito A, Nakano M, Takasaki K. Hepatocellular carcinoma with central scar and a scalloped tumor margin resembling focal nodular hyperplasia in macroscopic appearance. J Surg Onc 2006; 94: 587-591
3. Cherqui D. Les tumeurs bénignes du joie. J Chir (Paris) 2001; 138: 19-26
4. Cazals-Hatem D, Vilgrain V, Genin P, et al. Arterial and portal circulation and parenchymal changes in Budd-Chiari syndrome: a study in 17 explanted livers. Hepatology 2003; 37: 510-519